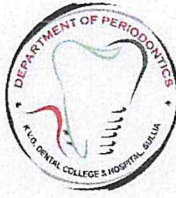
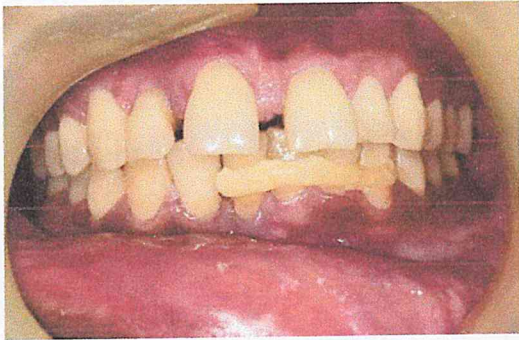




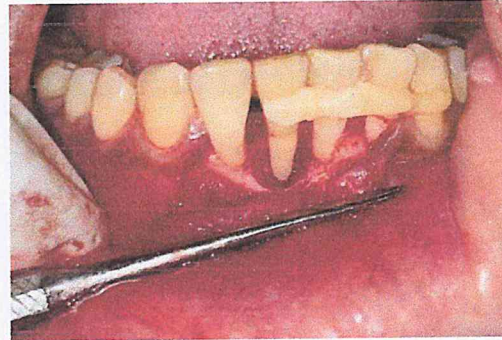
**K.V.G. DENTAL COLLEGE & HOSPITAL**  
KURUNJIBAG – 574 327, SULLIA, Dakshina Kannada [Karnataka State] India  
SPONSORED BY ACADEMY OF LIBERAL EDUCATION (REGD.) SULLIA  
Recognized by DCI, New Delhi & Affiliated to RGUHS, Karnataka  
Phone: 08257-235148/230148 Website: [www.kvgdentalcollege.org](http://www.kvgdentalcollege.org)



### REGENERATIVE FLAP SURGERY

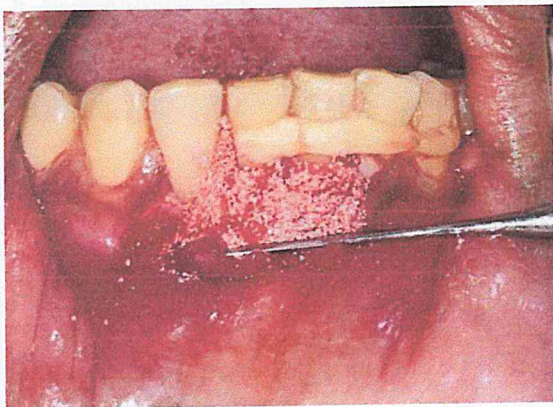


Pre operative

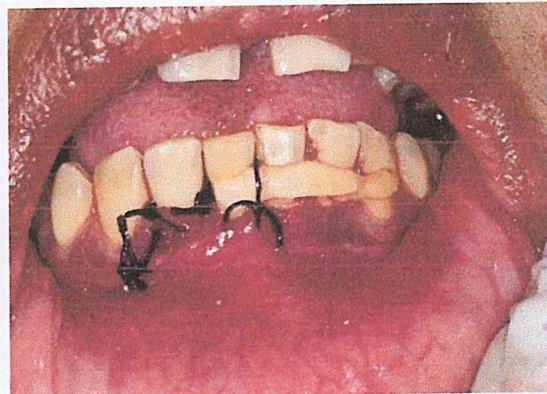


Full thickness mucoperiosteal flap elevated,


Debridement done wrt 41



Bone graft placed wrt 41



Suture placed

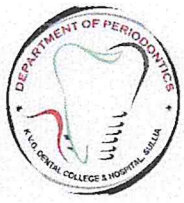
  
PRINCIPAL  
K.V.G Dental College & Hospital  
Kurunjibag, Sullia, D.K. - 574327

  
Dr. M.M. DAYAKAR M.D.S.  
Professor & H.O.D  
Department of Periodontics  
K.V.G. Dental College & Hospital  
Sullia D.K. - 574 327

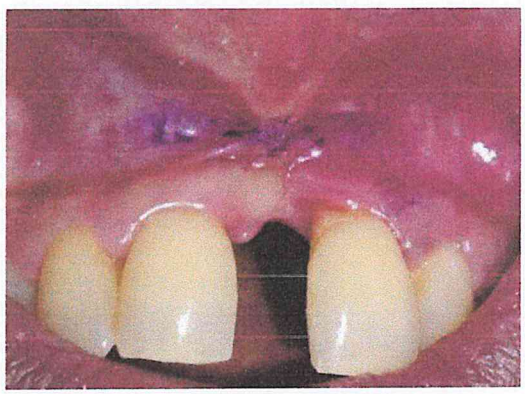


**K.V.G. DENTAL COLLEGE & HOSPITAL**

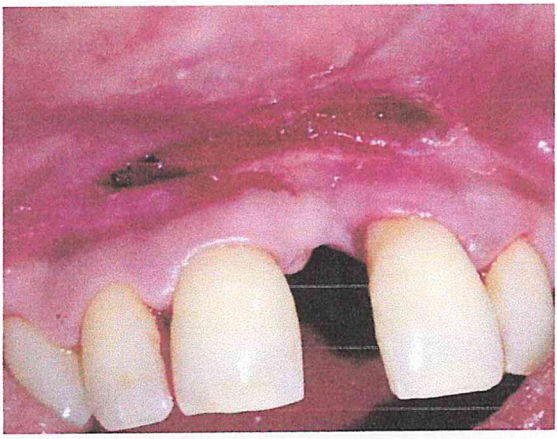
KURUNJIBAG – 574 327, SULLIA, Dakshina Kannada [Karnataka State] India  
SPONSORED BY ACADEMY OF LIBERAL EDUCATION (REGD.) SULLIA  
Recognized by DCI, New Delhi & Affiliated to RGUHS, Karnataka  
Phone: 08257-235148/230148 Website: [www.kvgdentalcollege.org](http://www.kvgdentalcollege.org)



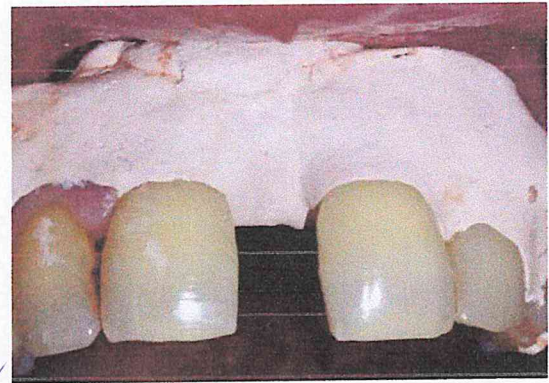
**Maxillary vestibuloplasty**



Pre operative



Intraoperative



Post – operative


*D. e.*  
**Dr. M.M. DAYAKAR M.D.S.**  
Professor & H.O.D  
Department of Periodontics  
K.V.G. Dental College & Hospital  
Sullia D.K. - 574 327

*[Signature]*  
**PRINCIPAL**  
K.V.G Dental Collage & Hospital  
Kurunjibag, Sullia, D.K. - 574327

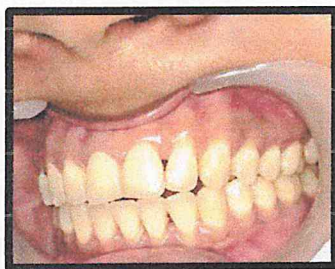


**K.V.G. DENTAL COLLEGE & HOSPITAL**

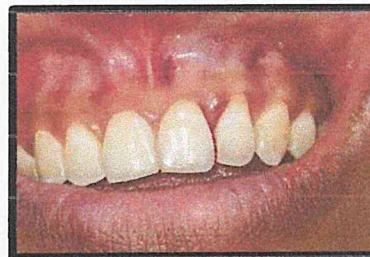KURUNJIBAG – 574 327, SULLIA, Dakshina Kamada [Karnataka State] India  
SPONSORED BY ACADEMY OF LIBERAL EDUCATION (REGD.) SULLIA  
Recognized by DCI, New Delhi & Affiliated to RGUHS, Karnataka  
Phone: 08257-235148/230148 Website: [www.kvgdentalcollege.org](http://www.kvgdentalcollege.org)



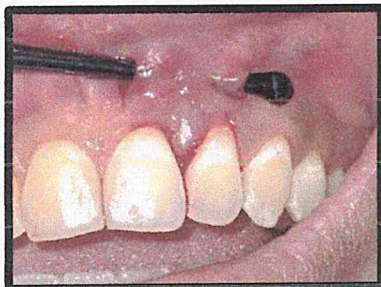**PAPILLARY RECONSTRUCTION VIA INCISION AND SUBMUCOSAL MOBILIZATION (PRISM) TECHNIQUE**



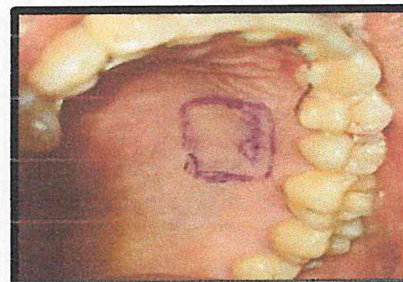
**Preoperative**



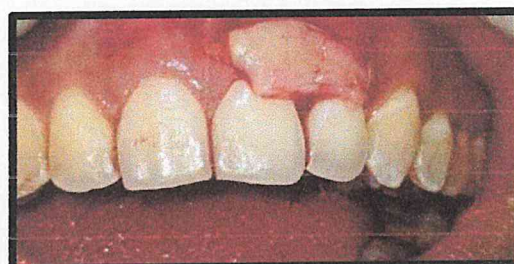**Markings done for incision**




**A TUNNEL IS CREATED USING TUNNELLING KNIFE**



**INTRA- OPERATIVE DONOR SITE MARKING ON THE LATERAL PALATE**



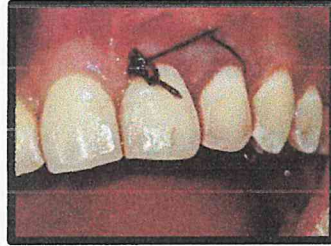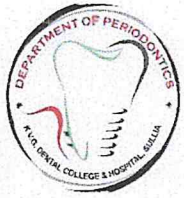
**CONNECTIVE TISSUE GRAFT TAKEN FROM THE PALATE AND PLACED ON THE RECEPIENT SITE**

  
**PRINCIPAL**  
K.V.G Dental College & Hospital  
Kurunjibag, Sullia, D.K. - 574327



**K.V.G. DENTAL COLLEGE & HOSPITAL**

KURUNJIBAG – 574 327, SULLIA, Dakshina Kannada [Karnataka State] India  
SPONSORED BY ACADEMY OF LIBERAL EDUCATION (REGD.) SULLIA  
Recognized by DCI, New Delhi & Affiliated to RGUHS, Karnataka  
Phone: 08257-235148/230148 Website: [www.kvgdentalcollege.org](http://www.kvgdentalcollege.org)



**POST- OPERATIVE SUTURING DONE**

**PRINCIPAL**

K.V.G Dental College & Hospital  
Kurunjibag, Sullia, D.K. - 574327

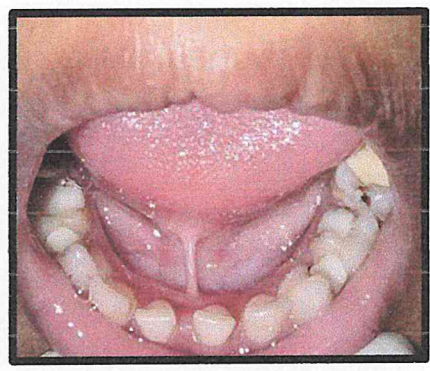
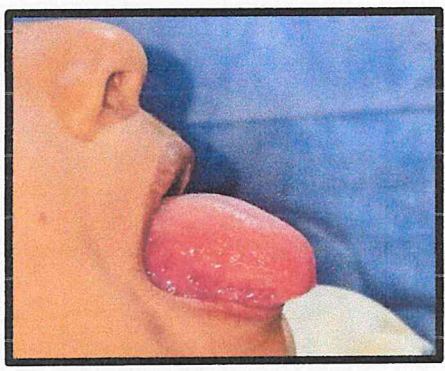
**Dr. M.M. DAYAKAR M.D.S.**  
Professor & H.O.D  
Department of Periodontics  
K.V.G. Dental College & Hospital  
Sullia D.K. - 574 327



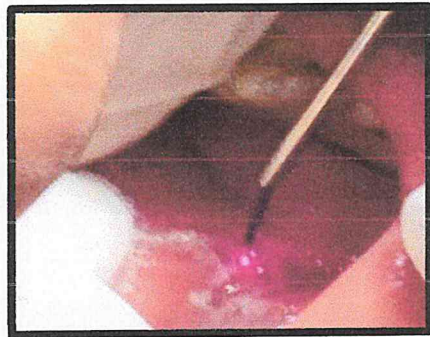
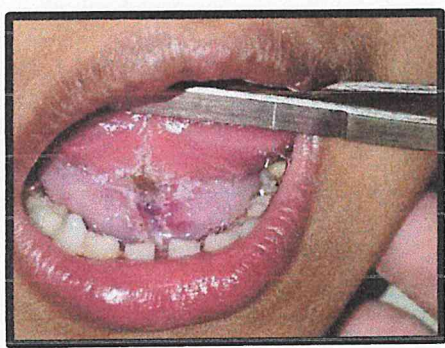
**K.V.G. DENTAL COLLEGE & HOSPITAL**  
KURUNJIBAG – 574 327, SULLIA, Dakshina Kannada [Karnataka State] India  
SPONSORED BY ACADEMY OF LIBERAL EDUCATION (REGD.) SULLIA  
Recognized by DCI, New Delhi & Affiliated to RGUHS, Karnataka  
Phone: 08257-235148/230148 Website: [www.kvgdentalcollege.org](http://www.kvgdentalcollege.org)



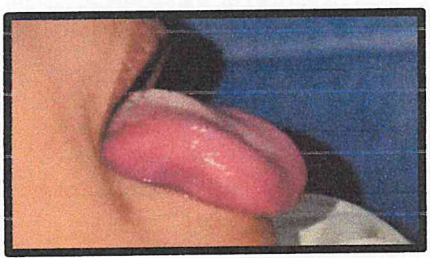
### LINGUAL FRENECTOMY ( TONGUE TIE)




Pre operative



### LASER APPLICATION FOR EXCISION OF LINGUAL FRENUM



Post operative

  
**PRINCIPAL**  
K.V.G Dental College & Hospital  
Kurunjibag, Sullia, D.K. - 574327